

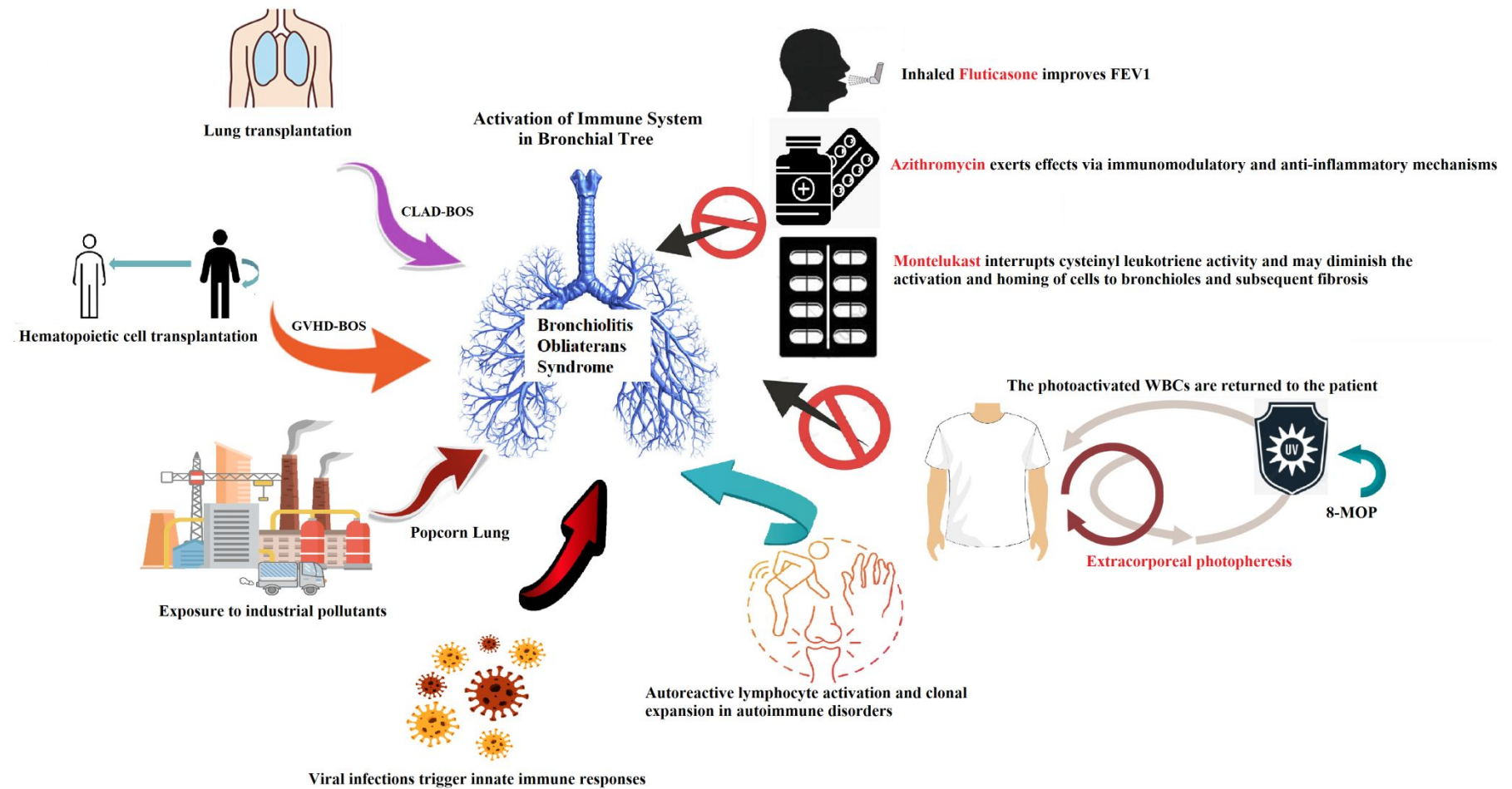
## Extracorporeal Photopheresis Versus FAM Therapy in Hematopoietic Cell Transplant Patients with Bronchiolitis Obliterans—What We Understand and What Remains Unclear

Journal:	<i>SAGE Open Medicine</i>
Manuscript ID	SOM-25-0841
Manuscript Type:	Review
Date Submitted by the Author:	30-Jun-2025
Complete List of Authors:	Wang, Yi-Lun; Chang Gung Memorial Hospital Linkou, Department of Pediatric Hematology/Oncology Lee, Wan-Ju; Mackay Memorial Hospital, Department of Radiation Oncology Wen, Yu-Chuan; Chang Gung Memorial Hospital Linkou Main Branch, Department of Nursing Hsiao, Yi-Wen; Chang Gung Memorial Hospital Linkou Main Branch, Department of Nursing Chang, Tsung-Yen ; Chang Gung Memorial Hospital Linkou Main Branch, Department of Pediatric Hematology/Oncology Jaing , Tang-Her; Chang Gung Memorial Hospital Linkou Main Branch, Department of Pediatric Hematology/Oncology
Keywords:	Extracorporeal photopheresis, FAM therapy, Bronchiolitis obliterans syndrome
Additional Keywords:	Hematopoietic cell transplantation, Children
Abstract:	Chronic graft-versus-host disease (cGVHD) is a significant late complication following allogeneic hematopoietic cell transplantation (HCT), with bronchiolitis obliterans syndrome (BOS), which is the primary lung manifestation associated with this condition. BOS results from a complex interplay of immune responses, environmental exposures, and transplant-related complications, leading to irreversible damage and scarring of the small airways in the lungs. Extracorporeal photopheresis (ECP) is one modality that has shown promise in slowing lung function decline in patients with progressive BOS, particularly after lung transplantation. Moreover, various research has underscored the comparison between ECP and FAM therapy for BOS, highlighting the necessity of adjusting therapies following immunosuppressive therapy. FAM therapy, a combination of inhaled Fluticasone, Azithromycin, and Montelukast, is increasingly recognized as a treatment option for BOS, especially after HCT. This study seeks to assess the efficacy of ECP compared to FAM therapy in the management of BOS in patients following HCT. The study used databases like PubMed, Embase, Cochrane Library, and ClinicalTrials.gov, as well as reference lists of relevant studies. The selection criteria included prospective trials that compared ECP with FAM treatment in patients experiencing BOS after HCT.

1  
2  
3  
4  
5  
6  
7  
8  
9  
10  
11  
12  
13  
14  
15  
16  
17  
18  
19  
20  
21  
22  
23  
24  
25  
26  
27  
28  
29  
30  
31  
32  
33  
34  
35  
36  
37  
38  
39  
40  
41  
42  
43  
44  
45  
46  
47  
48  
49  
50  
51  
52  
53  
54  
55  
56  
57  
58  
59  
60



## Graphical Abstract



**Extracorporeal Photopheresis Versus FAM Therapy in Hematopoietic Cell Transplant Patients with Bronchiolitis Obliterans: What We Understand and What Remains Unclear**

Yi-Lun Wang<sup>1</sup>, Wan-Ju Lee<sup>2</sup>, Yu-Chuan Wen<sup>3</sup>, Yi-Wen Hsiao<sup>3</sup>, Tsung-Yen Chang<sup>1</sup>,  
Tang-Her Jaing<sup>1\*</sup>

- 1. Division of Hematology and Oncology, Department of Pediatrics, Chang Gung Memorial Hospital, Taoyuan, Taiwan
- 2. Department of Radiation Oncology, Mackay Memorial Hospital, Taipei, Taiwan
- 3. Division of Nursing, Chang Gung Memorial Hospital, Taoyuan, Taiwan

Running title: Bronchiolitis obliterans syndrome after HCT

Address correspondence to:

**Tang-Her Jaing, MD.**

Division of Hematology and Oncology, Department of Pediatrics, Chang Gung Memorial Hospital, Chang Gung University  
5 Fu-Shin Street, Kwei-Shan 33315, Taoyuan, Taiwan

Email: [jaing001@cgmh.org.tw](mailto:jaing001@cgmh.org.tw)

Text word count: 1846

Abstract word count: 184

**Keywords:** Extracorporeal photopheresis, FAM therapy, bronchiolitis obliterans syndrome, hematopoietic cell transplantation

Tables: 2

Figures: 2

For Peer Review

**Abstract**

Chronic graft-versus-host disease (cGVHD) is a significant late complication following allogeneic hematopoietic cell transplantation (HCT), with bronchiolitis obliterans syndrome (BOS) being the primary lung manifestation associated with this condition. BOS results from a complex interplay of immune responses, environmental exposures, and transplant-related complications, leading to irreversible damage and scarring of the small airways in the lungs. Extracorporeal photopheresis (ECP) is one modality that has shown promise in slowing lung function decline in patients with progressive BOS, particularly after lung transplantation. Moreover, various research has underscored the comparison between ECP and FAM therapy for BOS, highlighting the necessity of adjusting therapies following immunosuppressive therapy. FAM therapy, a combination of inhaled Fluticasone, Azithromycin, and Montelukast, is increasingly recognized as a treatment option for BOS, especially after HCT. This study seeks to assess the efficacy of ECP compared to FAM therapy in the management of BOS in patients following HCT. The study used databases like PubMed, Embase, Cochrane Library, and ClinicalTrials.gov, as well as reference lists of relevant studies. The selection criteria included prospective trials that compared ECP with FAM treatment in patients experiencing BOS after HCT.

## Understanding Bronchiolitis Obliterans Syndrome

Bronchiolitis Obliterans Syndrome (BOS) is a progressive inflammatory condition characterized by fibrosis and scarring of the small airways or bronchioles, ultimately leading to partial or complete obstruction. This obstruction results in decreased airflow and respiratory function that worsens over time. BOS represents a final common pathway of airway injury and repair, regardless of the initial triggering mechanism.

The primary cause of BOS is lung transplantation, where it manifests as chronic lung allograft dysfunction (CLAD)<sup>1,2</sup>. BOS is the primary cause of chronic rejection and late mortality in lung transplant recipients, impacting 50-60% of patients who survive more than five years after the transplant<sup>3</sup>. The immune system recognizes the transplanted lung tissue as foreign, triggering an inflammatory response that damages the bronchioles.

In addition to transplantation, various conditions and exposures can lead to or exacerbate BOS: Hematopoietic cell transplantation (HCT) can lead to the development of BOS as a result of chronic graft-versus-host disease (cGVHD). Inhaling toxic chemicals like diacetyl, found in food flavorings such as artificial butter in microwave popcorn, can result in "popcorn lung"<sup>4</sup>. Exposure to industrial pollutants such as nitrogen oxides, sulfur dioxide, ammonia, chlorine, and metal oxide fumes<sup>5</sup>; Severe respiratory infections, especially those caused by viruses such as adenovirus,

respiratory syncytial virus (RSV)<sup>6</sup>, influenza, and cytomegalovirus (CMV); Autoimmune disorders such as rheumatoid arthritis<sup>7</sup>, systemic lupus erythematosus, and Sjögren's syndrome, along with certain medications, can occur, though this is relatively rare.

BOS encompasses a complex interaction of immune-mediated inflammation, epithelial injury, abnormal tissue repair processes, and fibroproliferation at the molecular level. The ongoing cycle of injury and abnormal repair results in excessive collagen deposition, fibrosis, and the typical narrowing or complete blockage of the bronchiolar lumen<sup>8</sup>.

**Extracorporeal photopheresis (ECP)**

ECP is a therapy that utilizes leukapheresis to address refractory cutaneous T-cell lymphoma in patients diagnosed with Sézary Syndrome<sup>9</sup>. ECP is an immunomodulatory therapy that entails the ex vivo collection of mononuclear cells, their exposure to the photoactive compound 8-methoxypsoralen (8-MOP), subsequent ultraviolet-A irradiation, and the re-infusion of the processed cellular product. The ex vivo nature of ECP allows for targeted therapy, minimizing systemic side effects while enhancing the immune response against specific targets<sup>10</sup>. ECP has been a valid treatment method for over 30 years and has over 2 million treatments performed. Its



safety and efficacy make it an essential part of treatment methods.

Over the past 35 years, the therapeutic effect of ECP has remained unclear, but researchers are now focusing on an immunomodulatory approach that emphasizes dendritic antigen-presenting cells (DCs)<sup>11</sup>. The focus on DCs as key players in immune response modulation underscores their significance in both therapeutic strategies and potential immunotherapies<sup>12</sup>. ECP promotes the production of anti-inflammatory cytokines and may decrease pro-inflammatory cytokines, and in patients with cGVHD, it alters the cytokine profile to favor a Th2 immune response<sup>13</sup>. This results in the apoptosis of mononuclear cells and differentiation into various cell lineages, including regulatory T-cells (Tregs), which are crucial for down-regulating immune responses. ECP is now accepted in solid organ transplantation, but its definitive role remains unestablished.

### **Fluticasone, Azithromycin, and Montelukast (FAM) Therapy**

FAM therapy, combining inhaled Fluticasone, Azithromycin, and Montelukast, is gaining recognition for its potential benefits in treating BOS and other respiratory conditions. This therapeutic approach utilizes the anti-inflammatory and anti-fibrotic properties of its components to reduce disease progression and enhance patient outcomes<sup>14</sup>.

Studies show that FAM therapy is especially effective for patients experiencing new-onset BOS after HCT<sup>15</sup>. Research indicates that this combination can improve patient-reported outcomes and functional abilities, including enhancements observed in the 6-minute walk test<sup>16</sup>. FAM therapy may also decrease the need for systemic steroids, reducing the potential side effects linked to long-term corticosteroid use.

FAM therapy has been incorporated into standard treatments for cGVHD in pediatric populations, showcasing its versatility across various patient demographics. The rationale for using FAM therapy is its capacity to deliver targeted relief and potentially prevent complications associated with more aggressive systemic treatments. We seek to conduct a systematic review comparing ECF and FAM therapy in the management of BOS following HCT.

**Methods**

**Search Strategy and Selection Criteria**

This review was conducted and reported following the Preferred Reporting Items for Systematic Reviews and Meta-Analyses (PRISMA) guidelines. Two authors (Y.-L.W. and W.-J.L.) searched relevant studies in PubMed, Embase, the Cochrane Library, and ClinicalTrials.gov. The following keywords were used across different databases: FAM, ECP, and BOS. Articles published up to March 15, 2025, were included. Duplicate records were automatically removed using EndNote version 21.0 software.

Two authors (Y.-L.W. and W.-J.L.) independently screened and reviewed the articles.

Any discrepancies were resolved by consensus or through consultation with three

independent authors (Y.-C.W., Y.-W.H., and T.-Y.C).

The inclusion criteria for this review were as follows: (1) Patients diagnosed with BOS following HCT; (2) Patients treated with FAM or ECP for BOS management; (3) Studies reporting clinical outcomes after the aforementioned interventions. Studies were excluded if they met any of the following criteria: (1) Enrolled transplanted patients other than HCT recipients; (2) Reported results from different studies using the same dataset; (3) Lacked a prospective design or randomized controlled trial (RCT) methodology; (4) Lacked full-text availability; (5) Were not published in English; (6) Provided an unclear or poorly described intervention strategy. No restrictions were applied regarding the year of publication, study location, patient gender, age, or race. The final selection of articles for analysis was approved by an independent author (T.-H.J.).

## Outcome Measures

The primary outcome of this review was to assess the effectiveness of ECP and FAM in managing BOS after HCT. This was evaluated by comparing the grading of cGVHD, results of pulmonary function tests (PFT), and the dose reduction of corticosteroids between ECP-treated and FAM-treated patients. The secondary

outcome was the overall survival (OS) following different treatment modalities.

**Quality Assessment**

Two authors (Y.-L.W. and W.-J.L.) independently conducted the quality assessment. The risk of bias tool was used to evaluate the quality of the selected studies. Seven key domains, including confounding bias, participant selection, intervention assessment, deviations from intended interventions, missing data, outcome measurement, and selection of reported results, were assessed. Each domain was categorized as low, moderate, or serious risk. Discrepancies were resolved by consensus with another author (T.-H.J.).

**Results**

**Study Selection and Characteristics**

A comprehensive search of PubMed, Embase, the Cochrane Library, and ClinicalTrials.gov identified 210 records (Figure 1). After removing 48 duplicates, 162 records remained for screening. After reviewing titles and abstracts, 9 records were selected for full-text assessment. Following a thorough evaluation, one study was excluded. An additional five studies were removed due to duplicate study populations or irrelevant outcomes. Ultimately, three studies were included in the final analysis. A

summary of the enrolled studies is provided in Table 1. Table 2 summarizes the risk of bias in the enrolled articles. All included studies were conducted in the United States, and none were RCTs. Two studies prospectively examined the efficacy of ECP in BOS management<sup>17,18</sup>. However, both lacked a control group for comparison. One study prospectively assessed the effect of FAM in halting BOS progression<sup>19</sup>. This study used a historical control group instead of conducting a direct comparison within the same cohort. The lack of direct cohort comparisons limited the feasibility of conducting a meta-analysis. This reflects the limited research on optimal BOS treatment strategies after HCT and highlights the urgent need for high-quality RCTs in this field.

### Primary Outcome

Lucid *et al.* reported that ECP was an effective therapy for stabilizing rapidly declining PFT in two-thirds of patients with heavily pretreated BOS. The treatment response rate was 67%, with a median time of 25 days from treatment initiation to response<sup>17</sup>. Brownback *et al.* reported similar improvements in PFT and noted a significant reduction in corticosteroid dosage after ECP therapy. The average reduction in corticosteroids was 44.3% after 3 months of ECP therapy, 51.5% after 6 months of ECP therapy, and 71.1% after 6 months of ECP therapy, respectively<sup>18</sup>. Regarding FAM therapy, Williams *et al.* reported that FAM was well tolerated. At 3 months, 48% of patients achieved a 50% reduction in corticosteroid dose. Patient-reported outcomes

improved after 3 months of FAM therapy, but 36% of patients experienced treatment failure by 6 months<sup>19</sup>.

**Secondary Outcome**

All included studies confirmed the safety and tolerability of both ECP and FAM therapy. No treatment-related mortality was reported for either intervention. However, a limited number of patients died during both therapies, though their deaths were not attributed to the intended interventions. The exact causes of death were not disclosed in the included studies.

**Discussion**

Therapies for BOS associated with cGVHD utilize a variety of agents, including corticosteroids, mTOR inhibitors, azithromycin, montelukast, and imatinib<sup>20</sup>. ECP has the potential to improve GVHD scores and stabilize the decline in lung function associated with BOS following HCT. ECP possesses a distinctive capability to elicit two contrasting effects: it stimulates the immune system for the treatment of cutaneous T cell lymphoma, while simultaneously reducing T lymphocyte activity in instances of allograft rejection and GVHD.

cGVHD is a complication of allogeneic HCT, causing immune-mediated damage to organs like the lungs, skin, liver, and eyes. Recent research indicates a strong

correlation between BOS and cGVHD, suggesting donor T cells may play a crucial role<sup>21</sup>. Important insights can be gained from comparing ECP with FAM in the treatment of BOS. ECP may serve as a treatment, as it has shown the ability to stop the decline of lung function, especially FEV1, in patients with cGVHD associated with BOS. FAM therapy, on the other hand, has shown a statistically significant decrease in prednisone exposure among individuals receiving treatment, indicating that it might be a less harmful substitute.

The study suggests that both ECP and FAM treatment modalities have their advantages, but they target different aspects of BOS management. ECP focuses on immunological responses, improving lung function outcomes, while FAM optimizes corticosteroid use and minimizes side effects. The choice depends on individual patient profiles and clinical scenarios.

ECP demonstrates a commendable outcome when juxtaposed with FAM therapy, especially in enhancing FEV1 and minimizing steroid consumption among patients. Although ECP proves to be effective, the advantages it offers might not endure over time<sup>22</sup>. Conversely, FAM therapy can be delivered over longer durations, potentially positioning it as a more sustainable choice, even though its immediate effectiveness may be lower. Furthermore, exploring the potential of additional agents such as ruxolitinib as a supplementary therapy may improve treatment results for patients,

particularly for those facing steroid-refractory conditions. In summary, both ECP and FAM present unique strengths and weaknesses, indicating the necessity for tailored treatment strategies that align with the specific needs and reactions of patients.

**Conclusion**

This systematic review sought to assess the comparative effectiveness of ECP and FAM therapy in the management of BOS after HCT from a heuristic standpoint. Given the insufficient studies providing direct comparisons between ECP and FAM, a meta-analysis was not feasible. Consequently, we articulated the available evidence in a narrative format. The lack of RCTs underscores a significant deficiency in robust research within this domain. To enhance supportive care for patients with BOS following HCT and to improve long-term post-transplant outcomes, there is an urgent need for future large-scale, well-designed RCTs.

- Funding:** This research received no external funding.
- Institutional Review Board Statement:** Not applicable.
- Informed Consent Statement:** Not applicable.
- Data Availability Statement:** Not applicable
- Conflicts of Interest:** The authors declare no conflicts of interest.



## References

1. Gauthier JM, Hachem RR, Kreisel D. Update on Chronic Lung Allograft Dysfunction. *Curr Transplant Rep*. 2016;3(3):185-91.
2. Haider S, Durairajan N, Soubani AO. Noninfectious pulmonary complications of haematopoietic stem cell transplantation. *Eur Respir Rev*. 2020;29(156):190119.
3. Friedlander S, Pogatchnik B, Furuya Y, Allen T. Pulmonary transplant complications: a radiologic review. *J Cardiothorac Surg*. 2024;19(1):270.
4. van Rooy FG, Rooyackers JM, Prokop M, Houba R, Smit LA, Heederik DJ. Bronchiolitis obliterans syndrome in chemical workers producing diacetyl for food flavorings. *Am J Respir Crit Care Med*. 2007;176(5):498-504.
5. Gutor SS, Miller RF, Blackwell TS, Polosukhin VV. Environmental and occupational bronchiolitis obliterans: new reality. *EBioMedicine*. 2023 Sep;95:104760.
6. Gottlieb J, Zamora MR, Hodges T, Musk AW, Sommerwerk U, Dilling D, Arcasoy S, DeVincenzo J, Karsten V, Shah S, Bettencourt BR, Cehelsky J, Nochur S, Gollob J, Vaishnaw A, Simon AR, Glanville AR. ALN-RSV01 for prevention of bronchiolitis obliterans syndrome after respiratory syncytial virus infection in lung transplant recipients. *J Heart Lung Transplant*. 2016;35(2):213-21.

7. Lin E, Limper AH, Moua T. Obliterative bronchiolitis associated with  
rheumatoid arthritis: analysis of a single-center case series. BMC Pulm Med.  
2018;18(1):105.

8. Palmer SM, Flake GP, Kelly FL, Zhang HL, Nugent JL, Kirby PJ, Foley JF,  
Gwinn WM, Morgan DL. Severe airway epithelial injury, aberrant repair and  
bronchiolitis obliterans develops after diacetyl instillation in rats. PLoS One.  
2011;6(3):e17644.

9. Cho A, Jantschitsch C, Knobler R. Extracorporeal Photopheresis-An Overview.  
Front Med (Lausanne). 2018 Aug 27;5:236.

10. Futterleib JS, Feng H, Tigelaar RE, Choi J, Edelson RL. Activation of GILZ  
gene by photoactivated 8-methoxypsoralen: potential role of immunoregulatory  
dendritic cells in extracorporeal photochemotherapy. Transfus Apher Sci.  
2014;50(3):379-87.

11. Schülke S. Induction of Interleukin-10 Producing Dendritic Cells As a Tool to  
Suppress Allergen-Specific T Helper 2 Responses. Front Immunol. 2018;9:455.

12. Gardner A, de Mingo Pulido Á, Ruffell B. Dendritic Cells and Their Role in  
Immunotherapy. Front Immunol. 2020;11:924.

13. Mankarious M, Matthews NC, Snowden JA, Alfred A. Extracorporeal  
Photopheresis (ECP) and the Potential of Novel Biomarkers in Optimizing

- Management of Acute and Chronic Graft vs. Host Disease (GvHD). *Front Immunol.* 2020;11:81.
14. Norman BC, Jacobsohn DA, Williams KM, Au BK, Au MA, Lee SJ, Moravec CK, Chien JW. Fluticasone, azithromycin and montelukast therapy in reducing corticosteroid exposure in bronchiolitis obliterans syndrome after allogeneic hematopoietic SCT: a case series of eight patients. *Bone Marrow Transplant.* 2011;46(10):1369-73.
15. Williams KM. How I treat bronchiolitis obliterans syndrome after hematopoietic stem cell transplantation. *Blood.* 2017;129(4):448-55.
16. Williams KM, Cheng GS, Pusic I, Jagasia M, Burns L, Ho VT, Pidala J, Palmer J, Johnston L, Mayer S, Chien JW, Jacobsohn DA, Pavletic SZ, Martin PJ, Storer BE, Inamoto Y, Chai X, Flowers MED, Lee SJ. Fluticasone, Azithromycin, and Montelukast Treatment for New-Onset Bronchiolitis Obliterans Syndrome after Hematopoietic Cell Transplantation. *Biol Blood Marrow Transplant.* 2016;22(4):710-6.
17. Lucid CE, Savani BN, Engelhardt BG, Shah P, Clifton C, Greenhut SL, Vaughan LA, Kassim A, Schuening F, Jagasia M. Extracorporeal photopheresis in patients with refractory bronchiolitis obliterans developing after allo-SCT. *Bone Marrow Transplant.* 2011;46(3):426-9.

18. Brownback KR, Simpson SQ, Pitts LR, Polineni D, McGuirk JP, Ganguly S, Aljitawi OS, Lin TL, Singh A, Abhyankar S. Effect of extracorporeal photopheresis on lung function decline for severe bronchiolitis obliterans syndrome following allogeneic stem cell transplantation. *J Clin Apher.* 2016;31:347-52.

19. Williams KM, Cheng GS, Pusic I, Jagasia M, Burns L, Ho VT, Pidala J, Palmer J, Johnston L, Mayer S, Chien JW, Jacobsohn DA, Pavletic SZ, Martin PJ, Storer BE, Inamoto Y, Chai X, Flowers MED, Lee SJ. Fluticasone, Azithromycin, and Montelukast Treatment for New-Onset Bronchiolitis Obliterans Syndrome after Hematopoietic Cell Transplantation. *Biol Blood Marrow Transplant.* 2016;22(4):710-6.

20. Sengsayadeth SM, Srivastava S, Jagasia M, Savani BN. Time to explore preventive and novel therapies for bronchiolitis obliterans syndrome after allogeneic hematopoietic stem cell transplantation. *Biol Blood Marrow Transplant.* 2012;18(10):1479-87.

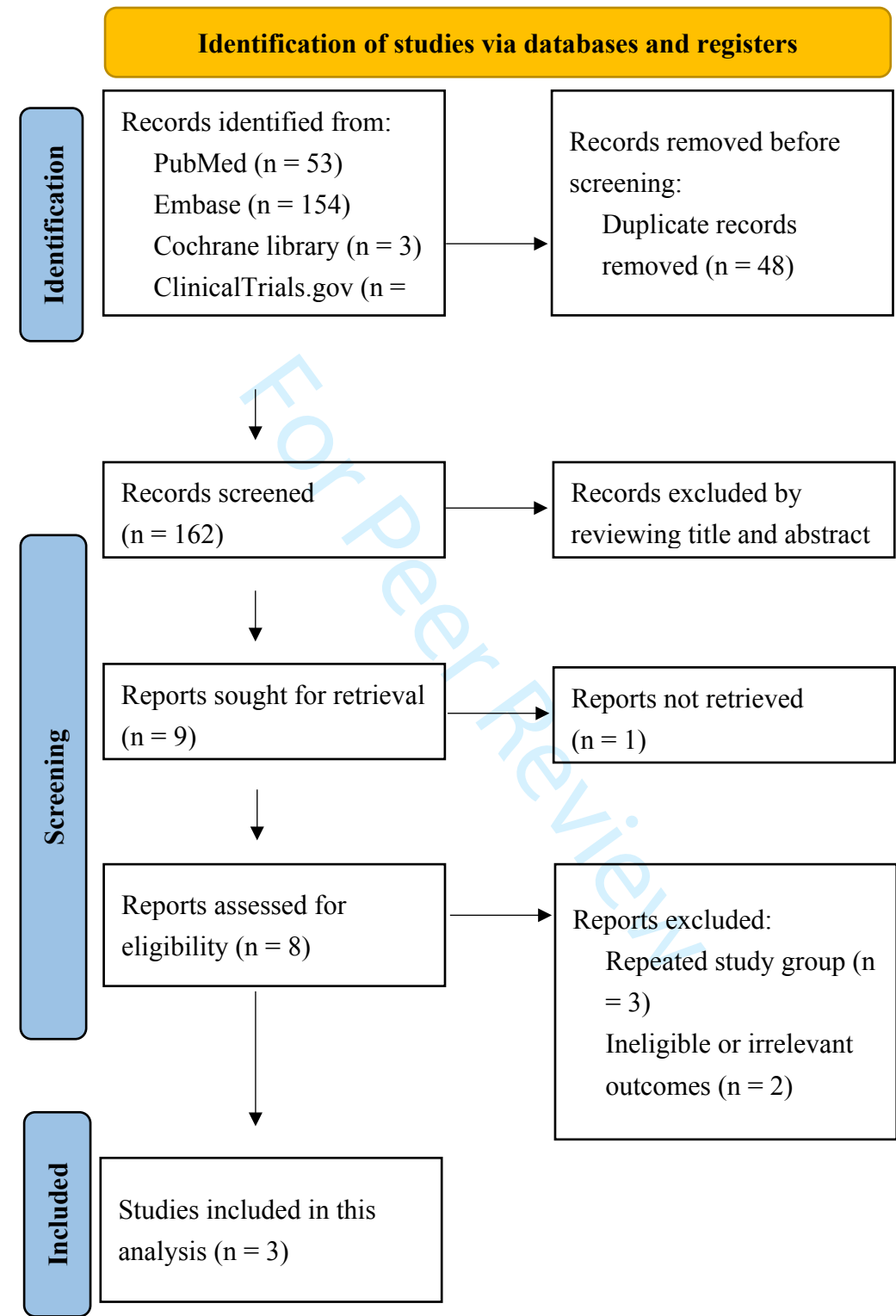
21. Cooke KR, Luznik L, Sarantopoulos S, Hakim FT, Jagasia M, Fowler DH, van den Brink MRM, Hansen JA, Parkman R, Miklos DB, Martin PJ, Paczesny S, Vogelsang G, Pavletic S, Ritz J, Schultz KR, Blazar BR. The Biology of Chronic Graft-versus-Host Disease: A Task Force Report from the National Institutes of

Health Consensus Development Project on Criteria for Clinical Trials in Chronic

Graft-versus-Host Disease. *Biol Blood Marrow Transplant*. 2017;23(2):211-34.

22. Knobler R, Barr ML, Couriel DR, Ferrara JL, French LE, Jaksch P, Reinisch W, Rook AH, Schwarz T, Greinix H. Extracorporeal photopheresis: past, present, and future. *J Am Acad Dermatol*. 2009;61(4):652-65.

**Figure 1.** Preferred Reporting Items for Systematic Reviews and Meta-Analysis (PRISMA) 2020 flow diagram for the analysis.






























**Table 1.** Summary of Enrolled Studies

Author, Year	Country	Study Type	Treatment	Number of Patients	Median Age (range)	Male (%)	Outcome
Williams, 2016	US	Prospective	FAM	36	57 (23-72)	53%	PFT, cGVHD, QoL, steroid taper
Lucid, 2010	US	Prospective	ECP	9	38 (21-54)	44%	PFT
Brownback, 2015	US	Prospective	ECP	8	43.5 (27-54)	63%	PFT, OS, steroid taper

Abbreviations: cGVHD, chronic graft-versus-host disease; ECP, extracorporeal photopheresis; FAM, fluticasone/azithromycin/montelukast; OS, overall survival; PFT, pulmonary function tests; QoL, quality of life; US, United States.

1  
2  
3  
4  
5  
6  
7  
8  
9  
10  
11  
12  
13  
14  
15  
16  
17  
18  
19  
20  
21  
22  
23  
24  
25  
26  
27  
28  
29  
30  
31  
32  
33  
34  
35  
36  
37  
38  
39  
40  
41  
42  
43  
44  
45  
46

**Table 2.** Table summarizing the risk of bias

		Risk of bias domains							
		D1	D2	D3	D4	D5	D6	D7	Overall
Study	Williams 2016								
	Lucid 2010								
	Brownback 2015								
Domains:									Judgement
D1: Bias due to confounding.									 Serious
D2: Bias due to selection of participants.									 Moderate
D3: Bias in classification of interventions.									 Low
D4: Bias due to deviations from intended interventions.									
D5: Bias due to missing data.									
D6: Bias in measurement of outcomes.									
D7: Bias in selection of the reported result.									